

**DATE PRESENTING CLINICAL SIGNS**

5/11/2022 Poor appetite, dispensed Mirataz to stimulate appetite but it's not helping.

PATIENT

Chicken Watson

Current Medications: Mirataz.
 Lab Results: Elevated ALT: 243. ALP: 379. Total bilirubin: 0.4.
 Date of Previous IntraPet Ultrasound: No previous.
 Sedation: Not required to complete full diagnostic ultrasound.
 Stat Report: Not requested.

SPECIES

Imaging Performed By: Stephanie Pearce RDCS, RVT.

Feline

BREED

DSH

SEX

Neutered Male

AGE

5/3/2016

WEIGHT

7.7 lbs

ULTRASONOGRAPHIC EXAMINATION OF THE ABDOMEN**Urinary System**

The urinary bladder, trigone, and pelvic urethra are normal in thickness and the mucosal surface is smooth. The bladder lumen is mildly distended. A scant amount of echogenic debris is observed within the lumen. No masses, inflammatory changes or calculi are observed. The region of the trigone and the proximal urethra are normal.

The left kidney is normal size (3.73 cm in length); normal shape and architecture with smooth peripheral margins. There is a normal 1:3 cortex to medulla ratio with minimal loss of corticomedullary distinction. There is no evidence of pyelectasia, nephroliths, infarcts or hydroureter. Renal vasculature is normal.

The right kidney is normal size (3.64 cm in length); with a slightly irregular shape and architecture with smooth peripheral margins. There is a normal 1:3 cortex to medulla ratio with minimal loss of corticomedullary distinction. A pinpoint focus of mineralization is observed adjacent to the renal pelvis. There is no evidence of pyelectasia or hydroureter. Renal vasculature is normal.

INTERPRETED BY

Andrea Nicastro,
 DMV, Diplomate
 DACVIM (Small
 Animal
 Internal Medicine)

Adrenal Glands

The left adrenal gland is normal size (0.38 cm width). Normal shape and glandular echogenicity. The phrenicoabdominal vein and surrounding vasculature are normal.

The right adrenal gland is normal size (0.39 cm width). Normal shape and glandular echogenicity. The phrenicoabdominal vein and surrounding vasculature are normal.

HOSPITAL NAME

Parkville Animal
 Hospital

Spleen

The spleen is normal in size (0.64 cm in width at the level of the hilus) with a normal capsular contour. There is appropriate echogenicity and echotexture. No focal lesions are observed. Splenic vasculature is normal.

REFERRING VET

Dr. Mangini

Liver

The liver is subjectively normal in size with normal curvilinear peripheral contours. The parenchyma is hyperechoic relative to the spleen and diffusely homogeneous in appearance. No distinct focal lesions are observed. Vascular and biliary tracts are of normal volume with no evidence of congestion. The gall bladder lumen is moderately distended. The wall is thin and smooth. A small amount of aggregated echogenic partially dependent debris is observed within the lumen. The cystic and common bile ducts are normal/not seen.

INVOICE

10882

The gall bladder lumen is moderately distended. The wall is thin and smooth. A small amount of echogenic debris is observed within the lumen. The cystic and common bile ducts are normal.

Gastrointestinal

The gastric lumen contains shadowing material (1.99 cm in diameter). The gastric wall and pylorus are normal in thickness with a normal layering pattern. The pyloric outflow tract is patent. The shadowing material appears to extend into the proximal duodenum. The remaining small intestinal lumen is not dilated. The small intestinal wall is normal in thickness with a normal layering pattern. There is disruption in the normal 1:3 muscularis: mucosal ratio and thickening of the submucosal layer in most segments. Discreet masses are not identified. The ileocecolic junction and colonic wall are normal. There is no evidence of an obstructive pattern.

Pancreas

The region of the pancreas is isoechoic relative to surrounding omental fat. No obvious parenchymal abnormalities are observed. There is no evidence of regional inflammation or effusion.

Free Abdomen

There is no evidence of free fluid. A 0.53 cm gastric lumen node is visualized.

ULTRASONOGRAPHIC FINDINGS

Primary Findings

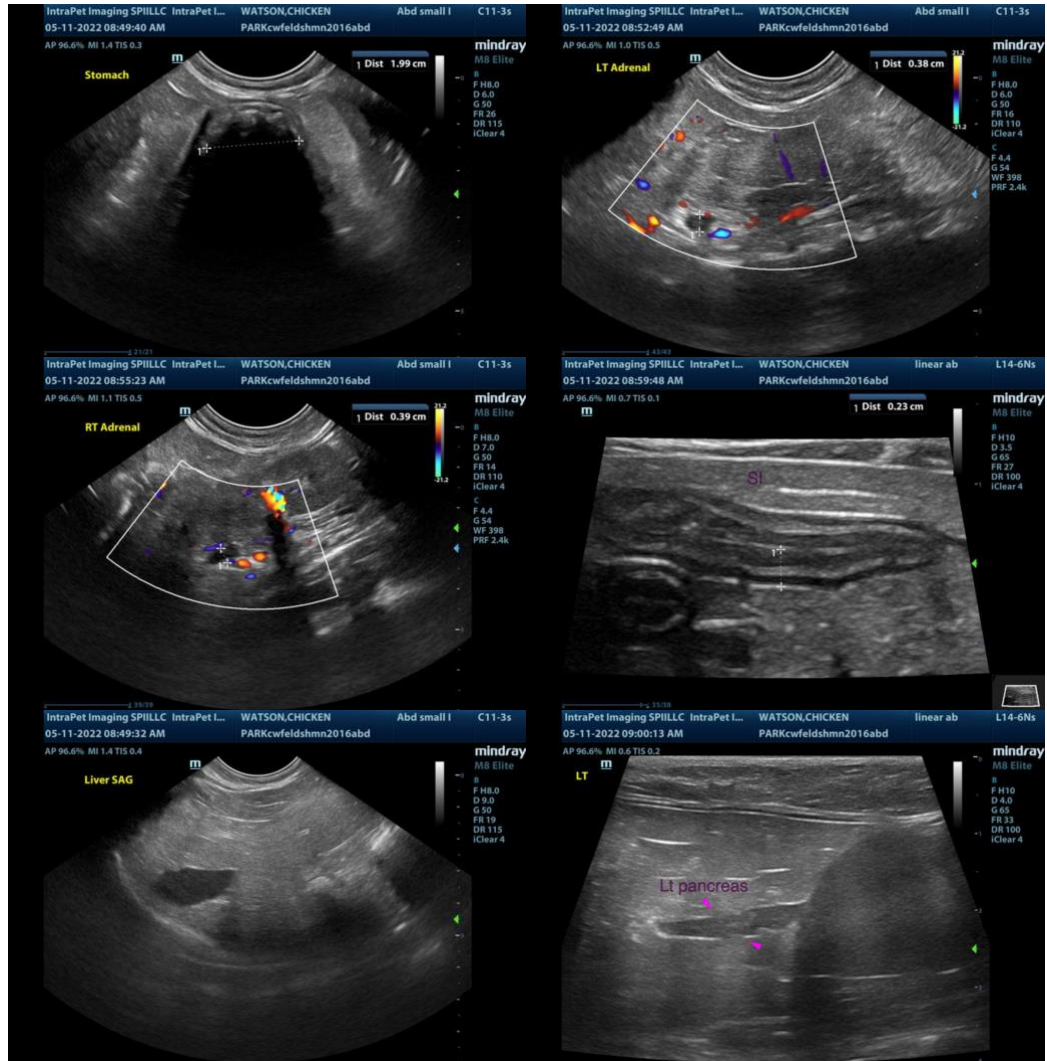
- Hepatic changes are non-specific and could be consistent with hepatic lipidosis, inflammatory/infectious disease, infiltrative neoplasia, or other hepatopathy.
- Bowel pattern consistent with inflammatory bowel disease. There is some potential for emerging lymphoma, however neoplasia is considered less likely at this time.
- The gastric luminal contents are concerning for foreign material. This may be affecting the patient's appetite.

Secondary Findings

- Small, nonobstructive right nephrolith

INTERPRETATION OF THE FINDINGS & FURTHER RECOMMENDATIONS

- Considered abdominal radiographs to further evaluate for gastric foreign material.
- Other diagnostic considerations include the following:
 1. Thoracic radiographs to assess cardiopulmonary status.
 2. Malabsorption panel, including serum cobalamin and folate, TLI and PLI.
 3. Fecal evaluation for ova and Giardia
 4. A fine-needle aspirate of the liver can be considered if clotting status is appropriate. Hepatic cytology is most useful in identifying round cell neoplasia and hepatic lipidosis in a cat but is less helpful in evaluating for inflammatory and other hepatopathies. Ultimately, surgical, hepatic, and gastrointestinal biopsies may be necessary to get a definitive diagnosis. If pursued, the stomach should be assessed for foreign material. While awaiting test results, consider aggressive nutritional support (i.e., via temporary feeding tube) to help prevent/treat hepatic lipidosis. Also consider empirical treatment for bacterial cholangiohepatitis (i.e., amoxicillin-clavulanic acid +/- metronidazole, Denamarin).



The information and recommendations provided are based on the images presented by the referring veterinarian/sonographer. No evaluation can be communicated regarding pathology that was not visible in the image/video clips provided.

Thank you for this referral. If the clinical or image interpretation does not parallel your findings or if I can be of any further assistance, please contact me.

Andrea Nicastro, DVM, Diplomate DACVIM (Small Animal Internal Medicine)
info@SonoPath.com